OSPE:

1- **Site of lumbar puncture in a 5 yrs old child**
2- **A question about the dentate nucleus**
3- **A question about the cranial nerves passing through: internal acoustic foramen, foramen rotundum and another foramen**
4- **A question about the medial geniculate**
5- **A question about Wernicke's area**
6- **A question about the layers of the peripheral nerve(epineruim,perineruim,endonerium)**
7- **An angiogram with a clinical case asking about the posterior cerebral artery**
8- **A micro question showing a picture of fungi asking to identify it (neoformans)**
9- **A question about the neuropathy**
10- 25 year old patient who had recovered from meningitis came to the clinic with severe headache, nausea and vomiting. His MRI reveals hydrocephalus.Which of the structures labelled as A, B, C, and D in the picture below will be affected in this case to cause hydrocephalus? A- Arachnoid granulations

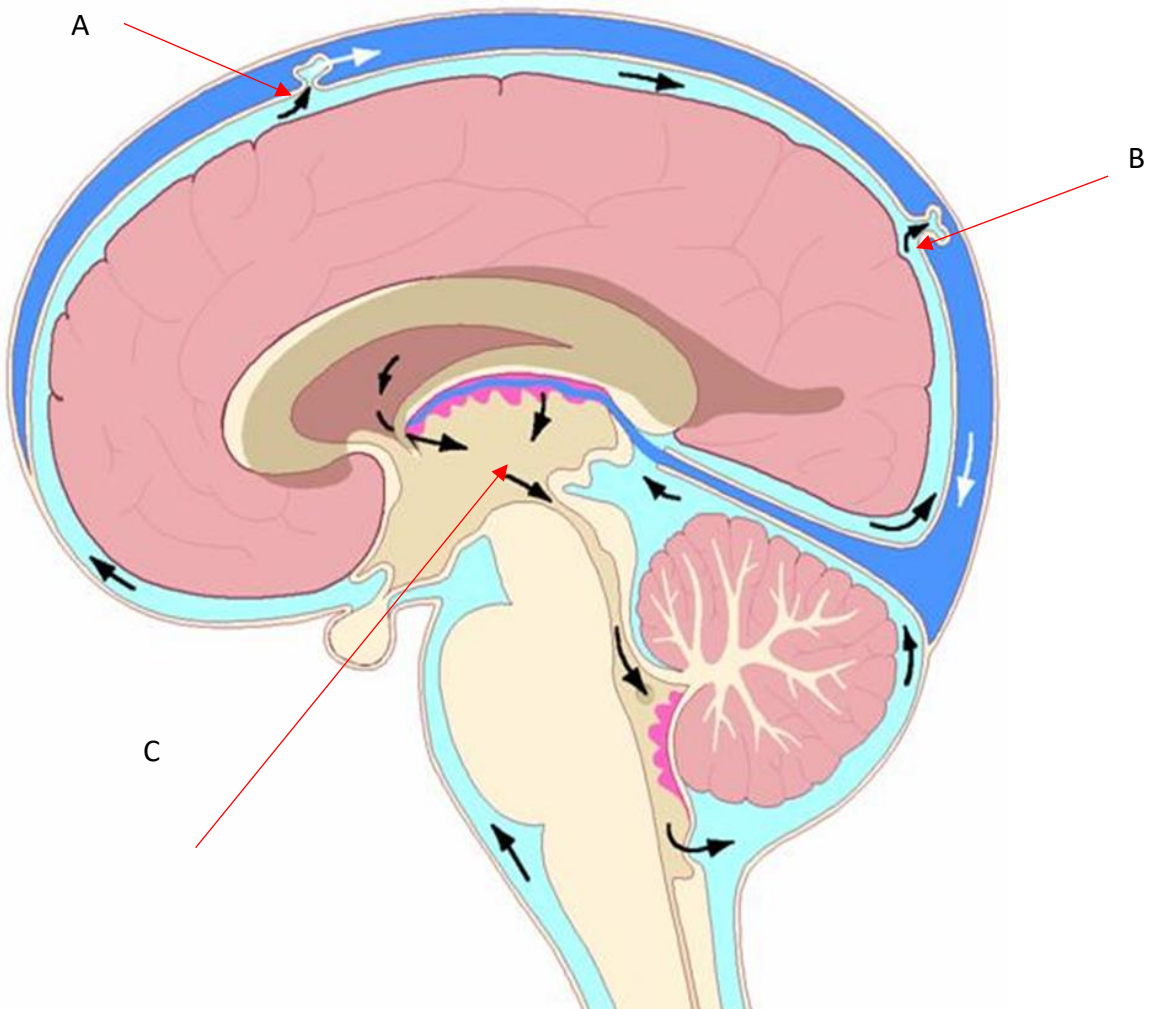

1. Peripheral nerve? 2 identification points?
2. Pointing at the pyramidal cells of the cerebrum
3. Viral meningitis > use PCR
4. Cryptococcus neoformens. Identify form a picture?

Ospe:

1. A 47 year old hypertensive patient comes with drooping on the right lower face, numbness in right arm and leg. Which structure is damaged? Which artery is affected? Thalamic stroke, Posterior cerebral artery
2. Which nerves pass through the labelled openings? Vb, Vc, 7 and 8th nerves
3. Two microscopic pictures: one showing the motor neurons in anterior horn and other showing purkenji cells of the cerebellum. Which of the following cells is involved in primary motor functions? Motor neuron
4. Damage to this area (superior temporal gyrus) will result in which symptoms and which artery is affected? Hearing loss, anterior cerebral artery
5. Where would you take the CSF from in a 5 year old child? L4-L5
6. Pill rolling tremor, which area is affected on the coronal picture?
7. Picture showing MGN and LGN, which of them is damaged in hearing loss?
8. Peripheral nerve identification. Name two points of identification
9. Two histology pictures showing nervous tissue. Which of them is showing myelinated fibres?
10. Person showing docility, hypersexualism due to? Removal of medial temporal lobes.
11. A child having encephalitis. Column showing CSF analysis. Which suitable test would you perform? NAAT
12. Immunocompromised patient having fungal meningitis. What is the organism? Cryptococcus neoformans
13. Which of the following forms the right transverse sinus? Superior sagittal sinus
14. In which part is the marked sinus (inferior sagittal sinus) located? Inferior margin of falx cerebri
15. A question about…To which Broadman’s area does it send signal to?

OSPE-

1. Station with the foramens in the skull asking to identify the nerves passing through
2. A) Identify the nuclei responsible for Nucleus solitaries
   B) What develops from the gray matter structure labelled X?

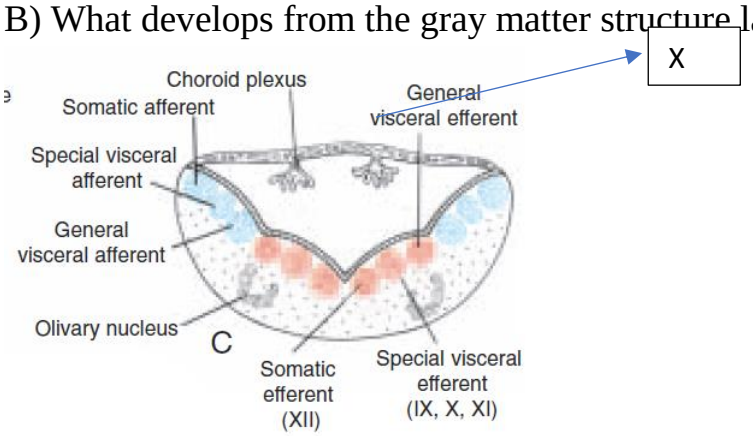

3. Model of the vertebral column with the lumbar wertebra labelled: Between which two vertebra would you perform a lumbar puncture on a 5 year old boy?

4. A)Picture of the thalamus with the nucle given: which of the following labelled nuclei acts as a relay for auditory information?
B)Where does it send it's output to?

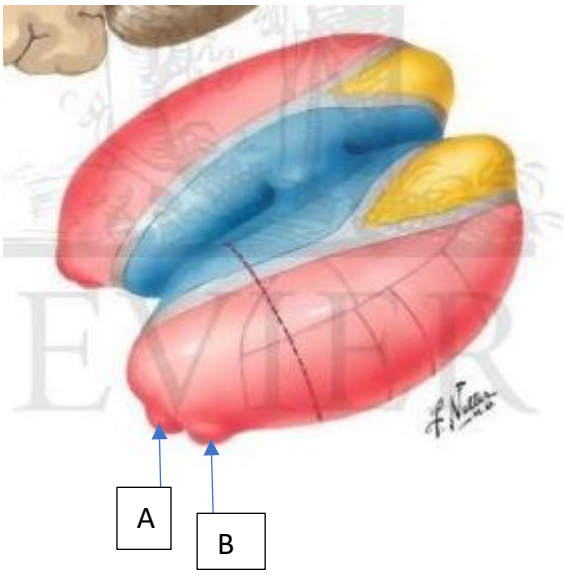

5. A) which of the following waves will be diminished when the person opens his eyes?
B) Provide a reason for your answer.



6. A) Identify the structure under the microscope.
B) Give two points of identification.

7. A) What organism was being studied?
B) Name the ink used.

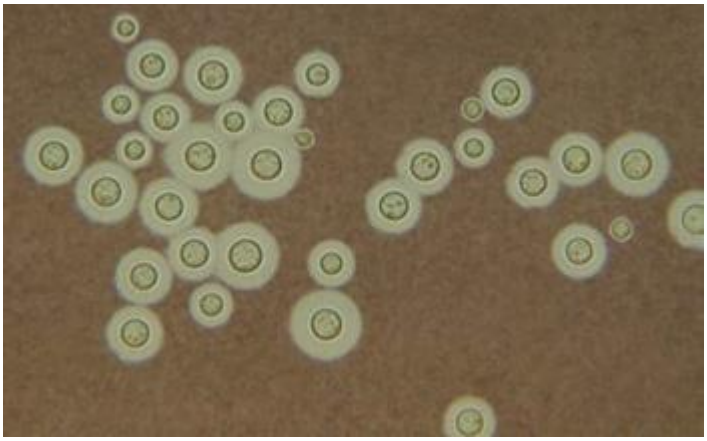

8. CSF analysis for a bacterial infection was shown:
A) What study would you order next?

1.Three qs about mca
2.Identify the organism? Streptococcus neoformas
3. Identify a virus type by NAAT
4. Corticospinal cervical part lesion
5. LP level
6. Damage to superior temporal lobe which artery and symptoms
7. Infection case with muscle power of 2/5 -> neuropathy on emg and why
8. Measuring a relax closed eye person then ask him to open eye which wave is distracted and why
9. Which one is responsible for taste development special visceral afferent (point on picture)
10. Basal artery infraction symptom (which artery)
11. Identify primary motor function cell pyramid on pic
12. Identify cross section peripheral nerve and 2 identification
13. Where do superior sagittal sinus drain to
14. Pointing at infer sagittal sinus and asking which dural fold is here falx cerebri
15. Auditory stimuli -MGB -primary auditory cortex 41-41